

News in Review

COMMENTARY AND PERSPECTIVE

RETINA

Novel Protocol for CNV: “Treat-Extend-Stop”

A VARIATION ON INTRAVITREAL

therapy, in which treatment intervals are first extended to 12 weeks and then injections are stopped altogether, can preserve the visual acuity (VA) of patients with wet age-related macular degeneration (AMD) even if their choroidal neovascularization (CNV) recurs, a study by California retina specialists has found.

Their retrospective analysis of outcomes with this “treat-extend-stop” (TES) protocol showed that 37.3% of 385 eyes treated for CNV met the criteria for cessation of therapy. Of these 143 eyes, 70.6% required no further intervention during a mean of 27 months of follow-up. In those that did have a recurrence, 54.8% recovered after retreatment to 20/40 or better, similar to the mean VA in the group when the injections were stopped.¹ Patients were able to maintain a 2-line gain in vision (10 letters), even after a recurrence.

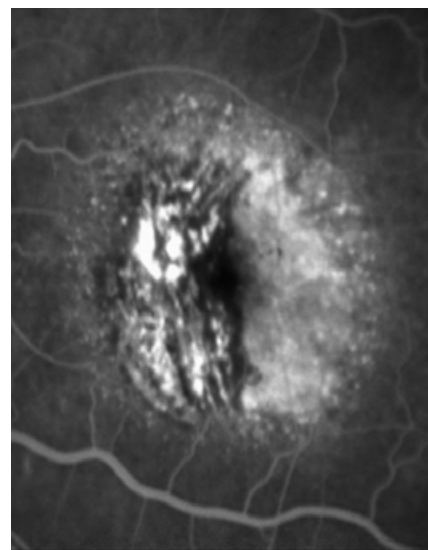
Rationale. “Originally I did this study just out of clinical curiosity. I wanted to know what percentage of patients had a recurrence of the CNV after we stopped therapy,” said coauthor Sean D. Adrean, MD, who practices in Fullerton, California. “I was relieved to find out that when patients had a recurrence, overall they did not lose vision.”

Dr. Adrean said that, based on the literature and on anecdotal reports from colleagues around the country, the most commonly used treat-and-extend protocol for intravitreal treatment of CNV lengthens the interval between injections to 10–12 weeks and continues this schedule indefinitely. But his analysis of 8 years of outcomes in his group’s practice suggests that many patients with wet AMD could benefit from the TES approach, he said.

“To know that you can actually stop injecting these patients and they can continue to do well, and only about 30% of eyes [experience a recurrence]—well, this means that you can maybe avoid doing unnecessary injections, or at least reduce the number of injections the patient needs,” Dr. Adrean said.

TES protocol. The authors described their TES protocol as follows:

- Therapy begins with at least 3 monthly injections of an anti-vascular endothelial growth factor (VEGF) agent, until a “dry” macula is confirmed with spectral-domain optical coherence tomography (SD-OCT).
- If the macula remains free of fluid, the intervals between injections are extended by 1 to 2 weeks between successive visits, until a 12-week time interval is reached.
- If the patient has received at least 7 total injections, and if SD-OCT at 3 successive 12-week visits confirms that CNV has not recurred, the injections are stopped.
- Patients return 1 month later and then successively longer by 2-week intervals until 12 weeks is reached. These



ACTIVE. A 30-degree fluorescein angiogram of an 80-year-old patient with wet AMD and active CNV.

patients are then monitored quarterly for signs of recurrence.

Monitoring a must. Because the study documented recurrences in a few TES patients as long as 3 years after the cessation of treatment, ongoing monitoring every 3 months is essential, Dr. Adrean said.

“I’m always very frank with them, and I say there’s a 30% chance that their CNV could come back. I tell them to come back earlier if they have increased distortion or decreased vision, so we can start treatment again if the CNV has recurred,” he said.

—Linda Roach

1 Adrean SD et al. *Ophthalmology Retina*. 2018; 2(3):224–229.

Relevant financial disclosures—Dr. Adrean: Genentech: C,S; Ohr Pharmaceuticals: C,S; Ophthotech: C,S; Regeneron: C,S; SciFluor Life Sciences: C,S.



MORE ONLINE. For additional images, see this article at aao.org/eyenet.

Preterm Births Associated With Corneal Aberrations

RESEARCHERS IN GERMANY REPORT that extreme prematurity itself—not necessarily the occurrence of retinopathy of prematurity (ROP)—is associated with increased higher-order aberrations of the cornea in former preterm infants.¹ These findings were unexpected, said lead author Achim Fieß, MD, at the University Medical Center in Mainz.

Study design. The prospective cross-sectional study compared the corneal shape of 226 former preterm infants, of a gestational age (GA) of ≤ 32 weeks, with 259 randomly selected children who had been born at full term (GA ≥ 37 weeks).

The researchers evaluated differences in various corneal aberrations in relation to gestational age and ROP occurrence in these children. The various aberrations included astigmatism, coma, spherical aberration, and root-mean square of higher-order aberrations.

The subjects ranged in age from 4 to 10 years, an age group selected because little is known about the association between prematurity and altered corneal shape in early childhood, Dr. Fieß said. “We decided to investigate this age group to provide new insights for corneal aberration development in this decisive time frame of vision development.”

Dr. Fieß added that the study was possible only because of modalities, such as Scheimpflug imaging, which allows no-contact examination of the anterior segment. This is ideal for ob-

serving children in detail.

Findings. In general, total corneal aberrations, both lower- and higher-order, increased as gestational age declined, with effects observed mainly on the anterior surface of the cornea.

Yet because infants on the older end of the preterm spectrum (GA of 29-32 weeks) had corneal aberrations comparable to those children born at full term, the researchers refined the age parameters into *moderate* and *extreme* prematurity. It was extreme prematurity that was associated with increased higher-order and lower-order aberrations of the total cornea.

Clinical implications. While corneal aberrations may be one of several factors contributing to increased refractive error and low visual function, particularly in former extreme preterm infants, the visual effects of aberrations are expected to be small compared to myo-

GLAUCOMA

Corneal Hysteresis: New Risk Factor for Glaucoma

RESEARCHERS WHO PREVIOUSLY REPORTED THAT corneal hysteresis (CH) was associated with glaucoma progression¹ have found that it should be considered a new risk factor for developing the disease.² For every 1 mm Hg reduction in CH, the risk of developing glaucoma increased 21%.

Study specifics. CH, a measure of the cornea’s viscoelasticity, is the difference (measured in mm Hg) between the pressure at which the cornea bends inward during an air jet applanation and the pressure at which it bends out.

For this prospective observational cohort study, the researchers evaluated 199 glaucoma suspects (287 eyes) who had a history of intraocular pressure (IOP) > 21 mm Hg and/or suspicious appearance of the optic nerve, with normal visual fields (VFs) at baseline. CH measurements were acquired at baseline using the Ocular Response Analyzer (ORA; Reichert Technologies), and the patients were followed an average of 4 years.

Results. Glaucoma development, defined as 3 consecutive abnormal standard automated perimetry tests during follow-up, occurred in 19% of eyes.

The study found that lower baseline corneal hysteresis measurements were significantly associated with increased risk of developing glaucomatous VF defects over time, even after adjusting for age, IOP, corneal

thickness, and pattern standard deviation.

At baseline, CH was lower in those who developed glaucoma than in those who did not develop glaucoma (CH of 9.5 mm Hg vs. 10.2 mm Hg).

Predictive power. The study also found that CH may be a stronger risk factor for glaucoma than central corneal thickness (CCT), said coauthor Felipe A. Medeiros, MD, PhD, at Duke University in Durham, North Carolina. He added that this finding probably is related to the fact that thickness is just 1 component related to corneal biomechanics.

But unlike CCT, which affects estimations of IOP, there appears to be only a weak relationship between CH and IOP. “Corneal hysteresis may actually act more like a surrogate marker for the biomechanical properties of tissues in the back of the eye,” Dr. Medeiros said.

What next? Now, along with IOP, age, and CCT, another risk factor has been added to the constellation of those associated with glaucoma. “The challenge,” said Dr. Medeiros, “is how to develop new objective risk calculators that merge all these factors.” In the meantime, he advised doctors to consider measuring CH in glaucoma suspects. Eyes with a low CH would probably need to be monitored more often or receive early treatment, he said.

—Miriam Karmel

1 Medeiros FA et al. *Ophthalmology*. 2013;120(8):1533-1540.

2 Susanna CN et al. *Am J Ophthalmol*. Published online Jan. 2, 2018.

Relevant financial disclosures—Dr. Medeiros: NIH: S; Reichert: C,S.

pia or astigmatism, Dr. Fieß said. “Our finding, therefore, is less important for guiding treatment than it is for suggesting a further reason for low visual acuity and refractive error in former preterm children.”

Does the effect persist? Dr. Fieß is currently investigating the effect of low birth weight on ocular morphology in an adult cohort. This may determine whether corneal aberrations persist into adulthood in former preterm infants.

In the meantime, he said, “Our study highlights that, in particular, gestational age less than 29 weeks affects corneal shape. Extreme early prematurity is one decisive factor affecting corneal aberrations.”
—Miriam Karmel

1 Fieß A et al. *Invest Ophthalmol Vis Sci*. 2017; 58(14):6374-6378.

Relevant financial disclosures—Dr. Fieß: None.

TRAUMA

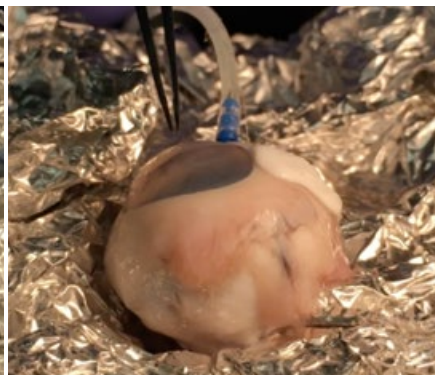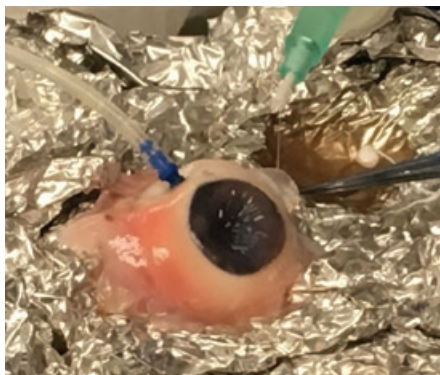
Compound Can Seal Scleral Injuries —Reversibly

RESEARCHERS AT THE UNIVERSITY

of Southern California (USC) hope the unique characteristics of their novel copolymer will solve an ophthalmic dilemma posed by combat- and mass-casualty-related ocular traumas. That is, scleral perforations sometimes must be left open for hours or even days before they can be repaired.

Thermoresponsive. The scientists chose a hydrophilic copolymer that was known to be thermoresponsive.¹ This property makes the material suitable for temporarily closing open-globe wounds without further damaging the tissue, particularly when resources, facilities, or time are limited.

The researchers found that military ophthalmologists and other clinicians were able to rapidly and reversibly occlude scleral perforations in animal eyes with the compound, which is a polymeric combination of N-isopropylacrylamide and butylacrylate—also called poly(NIPAM-co-BA), or N₉₅BA₅.



TEMPORARY CLOSURE. (Left) An ocular surgeon attempting to seal a large (~ 2 cm) full-thickness scleral laceration in a cannulated porcine eye using the ocular sealant and its associated customized injector tool designed by the team from USC. (Right) The same eye photographed 5 minutes later, with the sealant fixed in place and capable of maintaining IOP generated by the saline infusion cannula.

“We [have tailored] its thermo-responsive behavior and mechanical strength to create a hydrogel that shape-fills upon injection at a wound site, adapting to irregular margins and sealing traumatic injuries. The thermo-sensitive behavior allows the sealant ... to be easily removed by the application of cold water,” the authors wrote.

Material properties. Coauthor John J. Whalen, PhD, at USC’s Roski Eye Institute in Los Angeles, said that N₉₅BA₅ has the following properties:

- It exists as a viscous, translucent hydrophilic fluid at below 14 degrees Celsius (C). They designed a special double-walled (jacketed) syringe, capable of cooling the hydrogel on demand to below 10 degrees C for 10 minutes.
- It transitions to a more hydrophobic, opaque, sticky soft-solid state when body heat raises the temperature above 30 degrees C. This closes the wound and alleviates hypotony. (The solidification process takes approximately 5 minutes.)
- It returns to the liquid state when rehydrated with cold (< 10 degrees C) water, at which time the fluid can be aspirated away.

Early results. During in vivo testing in animals, the eyes showed some early signs of inflammation, which disappeared by 24 hours, the authors reported. There was no evidence of neurotoxicity, no retinal tissue degradation, and no significant chronic

inflammatory response to sustained exposure (30 days).

Potential applications. Delayed treatment for open-globe injuries has added importance today because of traumatic eye injuries from explosions in war zones and in mass-casualty events, such as the Boston Marathon bombing. In the former scenario, scleral perforations are left open while patients are airlifted to a hospital, sometimes thousands of miles away. In the latter, care for more critically injured patients might take precedence over open-globe injuries, Dr. Whalen said.

Dr. Whalen, who is a bioengineering materials specialist on the USC research team that conducted research supporting the Argus II retinal implant (Second Sight), said the group originally investigated hydrogel polymers to reversibly adhere the Argus II to the retina. But serendipity pointed them to open-globe injuries instead.

“We couldn’t quite get this compound to work with the Argus. But when we saw that the Army was looking for temporary treatments for ocular trauma, we wondered if our adhesive could do the trick—and, from the first bench-top experiment, we had success,” Dr. Whalen said. —Linda Roach

1 Bayat N et al. *Sci Transl Med*. 2017;9(419). doi: 10.1126/scitranslmed.aan.3879.

Relevant financial disclosures—Dr. Whalen: None.

See the financial disclosure key, page 8. For full disclosures, including category descriptions, view this News in Review at aao.org/eyenet.