

Z.G.J). R.W. is the recipient of the 2015 Nelson Trust Award for Retinitis Pigmentosa from Research to Prevent Blindness, Inc.

Human Subjects: Human subjects were included in this study. All participants in the study signed an informed consent that adhered to the tenets of the Declaration of Helsinki. Ethical approval for this study was obtained from the local institutional review board committees at the Hadassah-Hebrew University Medical Center and at Rambam Medical Center.

Author Contributions:

Conception and design: Kimchi, Wen, Sharon, Banin

Analysis and interpretation: Kimchi, Khateb, Wen, Guan, Obolensky, Beryozkin, Kurtzman, Pras, Jacobson, Ben-Yosef, Newman, Sharon, Banin
Data collection: Kimchi, Khateb, Wen, Guan, Obolensky, Beryozkin, Kurtzman, Blumenfeld, Pras, Jacobson, Ben-Yosef, Newman, Sharon, Banin

Obtained funding: none

Overall responsibility: Kimchi, Khateb, Wen, Guan, Obolensky, Beryozkin, Kurtzman, Blumenfeld, Pras, Jacobson, Ben-Yosef, Newman, Sharon, Banin

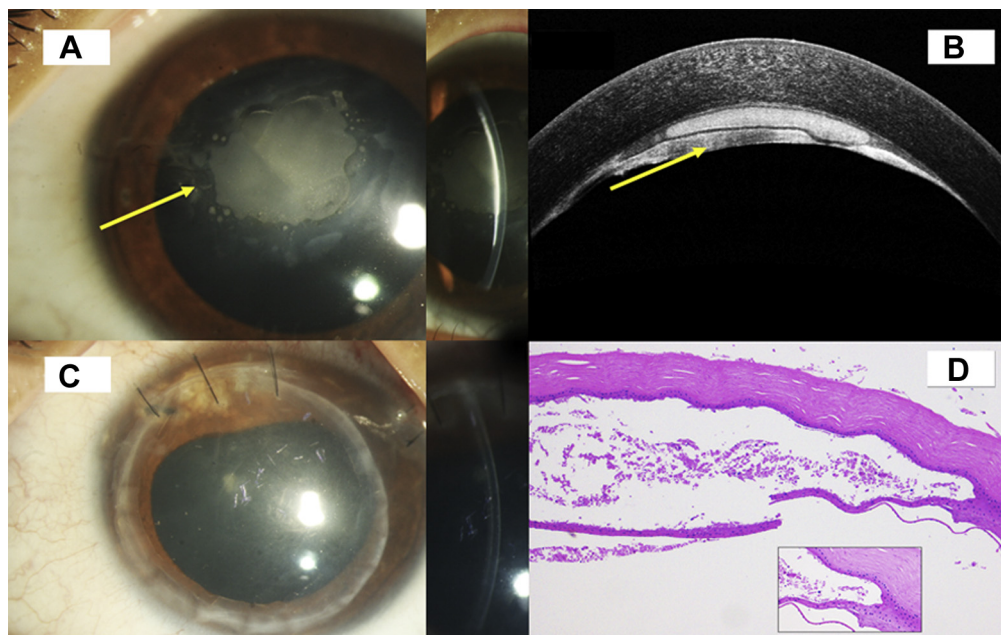
Abbreviations and Acronyms:

AD = autosomal dominant; **AJ** = Ashkenazi Jewish; **AR** = autosomal recessive; **BCVA** = best-corrected visual acuity; **BSP** = bone spicule; **EOG** = electro-oculography; **ERG** = electroretinography; **FA** = fluorescein angiography; **FAF** = fundus autofluorescence; **FC** = finger counting; **FFERG** = full-field electroretinography; **HM** = hand movement; **IRD** = inherited retinal degeneration; **LP** = light perception; **MAF** = minor allele frequency; **MAK** = male germ cell-associated kinase; **NLP** = no light perception; **ONL** = outer nuclear layer; **RP** = retinitis pigmentosa; **RPE** = retinal pigment epithelium; **VA** = visual acuity; **VF** = visual field; **WES** = whole exome sequencing; **XL** = X-linked.

Correspondence:

Dror Sharon, PhD, and Eyal Banin, MD, PhD, Department of Ophthalmology, Hadassah-Hebrew University Medical Center, Jerusalem, Israel. E-mail: dror.sharon1@gmail.com; banine@mail.huji.ac.il.

Pictures & Perspectives



Deep Lamellar Endothelial Keratoplasty for Epithelial Ingrowth

A 9-year-old child presented with left eye corneal opacity for 5 months followed by trauma with plastic stick. There was greyish white opacity (Fig 1A), which seemed to be a fluid collection with in the well-defined anterior and posterior wall (yellow arrow), confirmed with anterior segment OCT (Fig 1B). The diagnosis of posttraumatic intracorneal epithelial cyst was made. We performed deep lamellar endothelial keratoplasty. The patient showed well attached lenticule along with clear visual axis 2 months postoperatively (Fig 1C). On histopathology (Fig 1D), multilayered stratified epithelium could be appreciated in the cyst wall (magnified view in the inset). The patient completed 4 months of follow-up. (Magnified version of Fig 1A-D is available online at www.aaojournal.org.)

BHUPESH BAGGA, FRCS¹
SRIDHAR RAO, BSC²

¹Tej Kohli Cornea Institute, L.V. Prasad Eye Institute, Hyderabad, India; ²Ophthalmic Pathology Laboratory, L.V. Prasad Eye Institute, Hyderabad, India