

2. Rashid MHJ, Singh AD, Kivelä TT. Clinical predictors of regression of choroidal melanomas after brachytherapy: a growth curve model. *Ophthalmology*. 2018;125:747–754.
3. Konstantinidis L, Groenewald C, Coupland SE, Damato B. Trans-scleral local resection of toxic choroidal melanoma after proton beam radiotherapy. *Br J Ophthalmol*. 2014;98(6):775–779.
4. Hussain RN, Kalirai H, Groenewald C, et al. Prognostic biopsy of choroidal melanoma after proton beam radiation therapy. *Ophthalmology*. 2016;123(10):2264–2265.
5. Dogrusöz M, Kroes WG, van Duinen SG, et al. Radiation treatment affects chromosome testing in uveal melanoma. *Invest Ophthalmol Vis Sci*. 2015;56(10):5956–5964.

## Footnotes and Financial Disclosures

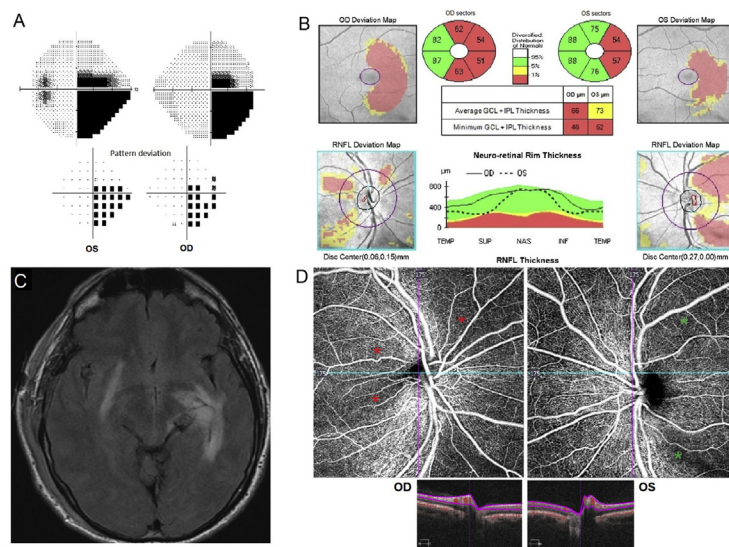
Financial Disclosure(s): The author(s) have no proprietary or commercial interest in any materials discussed in this article.

Supported in part by the National Eye Institute, National Institutes of Health, Bethesda, Maryland (grant no.: EY002162—Core Grant for Vision Research); and an unrestricted grant from Research to Prevent Blindness, Inc., New York, New York.

Correspondence:

Bertil Damato, MD, PhD, Ocular Oncology Service, University of California, San Francisco, CA 94143. E-mail: [Bertil.Damato@UCSF.edu](mailto:Bertil.Damato@UCSF.edu).

## Pictures & Perspectives



### Retinal Imaging of an Optic Tract Lesion: OCT Angiography of Structural and Functional Defects

A 44-year-old man presented with a 10-month history of right-sided vision loss. Humphrey visual fields showed a right, incomplete homonymous hemianopia (Fig 1A) secondary to a left optic tract metastasis from melanoma (Fig 1C). Homonymous macular ganglion cell complex loss and “bow-tie” retinal nerve fiber loss were demonstrated with OCT (Fig 1B). OCT-angiography showed dropout of capillaries in the retinal superficial vascular plexus centered on the optic discs in the areas of “bow-tie” atrophy (Fig 1D). Similar to optic neuropathies, loss of the superficial retinal capillary network occurs when the lesion is retrochiasmatal in the optic tract. (Magnified version of Fig 1A–D is available online at [www.aajournal.org](http://www.aajournal.org)).

JONATHAN A. MICELI, MD<sup>1</sup>  
 NANCY J. NEWMAN, MD<sup>1,2,3</sup>  
 VALÉRIE BIOUSSE, MD<sup>1,2</sup>

<sup>1</sup>Department of Ophthalmology, Emory University School of Medicine, Atlanta, Georgia; <sup>2</sup>Department of Neurology, Emory University School of Medicine, Atlanta, Georgia; <sup>3</sup>Department of Neurological Surgery, Emory University School of Medicine, Atlanta, Georgia

## Footnotes and Financial Disclosures

Financial Disclosure(s):

Supported in part by an unrestricted departmental grant (Department of Ophthalmology) from Research to Prevent Blindness, Inc., New York, and by NIH/NEI core grant P30-EY006360 (Department of Ophthalmology).